



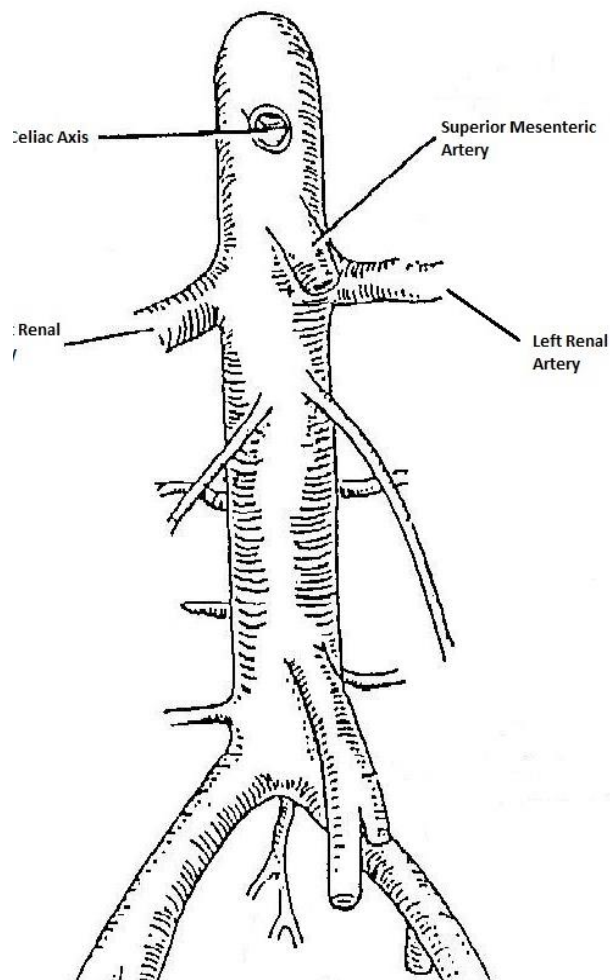
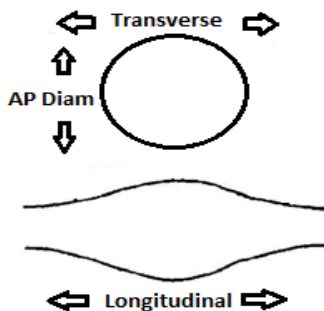
## CARDIORISK AAA SCREENING

Patient Name: Townsdin, Charles Date: 2/17/2021

DOB: 9/11/1941 Sex: M

Referring Provider: Robert Leff, MD

Vascular Technician: Ababel Luaibi



### Aorta Prox

2.3 cm Trans X 2.4 cm AP

### Aorta Mid

4.3 cm Trans X 4.5 cm AP

### Aorta Distal

1.9 cm Trans X 2.0 cm AP

Comments: There is a dilatation, saccular aneurysm of the mid segment of the abdominal aorta measuring 4.3 x 4.5 cm. It appears to be inferior to the renal arteries.



